METABOLIC & GENETIC DISEASES OF BONE

LAB-8

DR.NOOR

OSTEOGENESIS IMPERFECTA

- Osteogenesis imperfecta characterized by **impairment of collagen maturation.**
- Abnormal collagenous maturation results in bone with a **thin cortex, fine trabeculation, and diffuse osteoporosis.**
- Upon fracture, healing will occur but may be associated with exuberant callus formation .

Osteogenesis imperfecta.

A. **Opalescent** dentin in a patient with osteogenesis imperfecta.

B. Bite-wing radiograph of the same patient showing **thin** dentin and enamel of normal thickness.

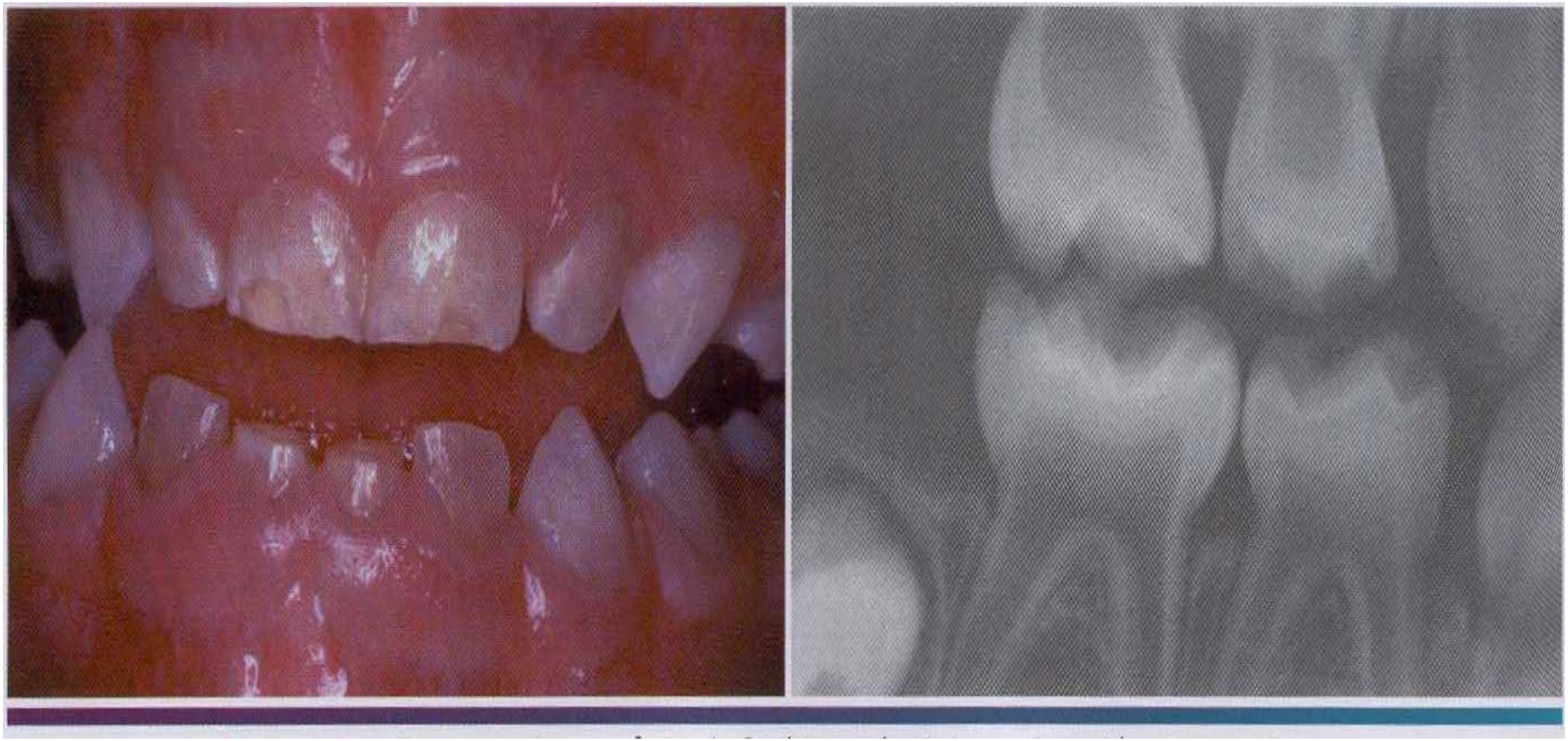

Blue sclera in a patient with **osteogenesis imperfecta**

Histopathologic Features

- Cortical bone appears attenuated.
- Osteoblasts are present, but bone matrix production is reduced markedly.
- The bone architecture remains immature throughout life.
- there is a failure of woven bone to become lamellar bone.

OSTEOPETROSIS (ALBERS-SCHONBERG DISEASE; MARBLE BONE DISEASE)

- Osteopetrosis is a marked increase in **bone density** resulting from a defect in remodeling caused by **failure of normal osteoclast function.**
- The number of osteoclasts present is often increased; however, because of their failure to function normally, bone is not resorbed. with continued bone formation and endochondral ossification, results in thickening of cortical bone and sclerosis of the cancellous bone.

Infantile. Osteopetrosis.

This 24 -year-old white man has the infantile form of osteopetrosis. He has suffered from mandibular osteomyelitis And multiple draining fistulae are present on his face.

A

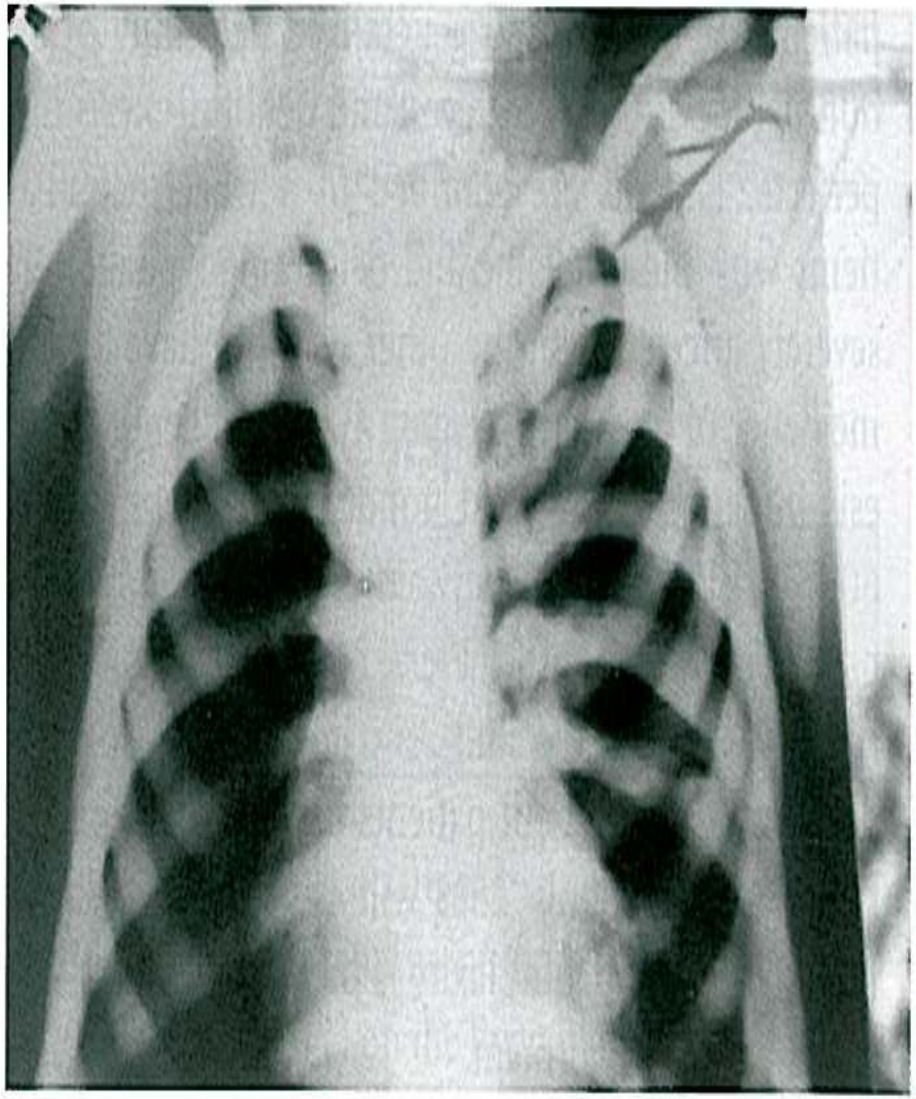

B

Osteopetrosis. A, Ribs, humerus, and clavicles exhibit increased bone density. **B,** Increase in bone density of cranial and base-of-skull bones.

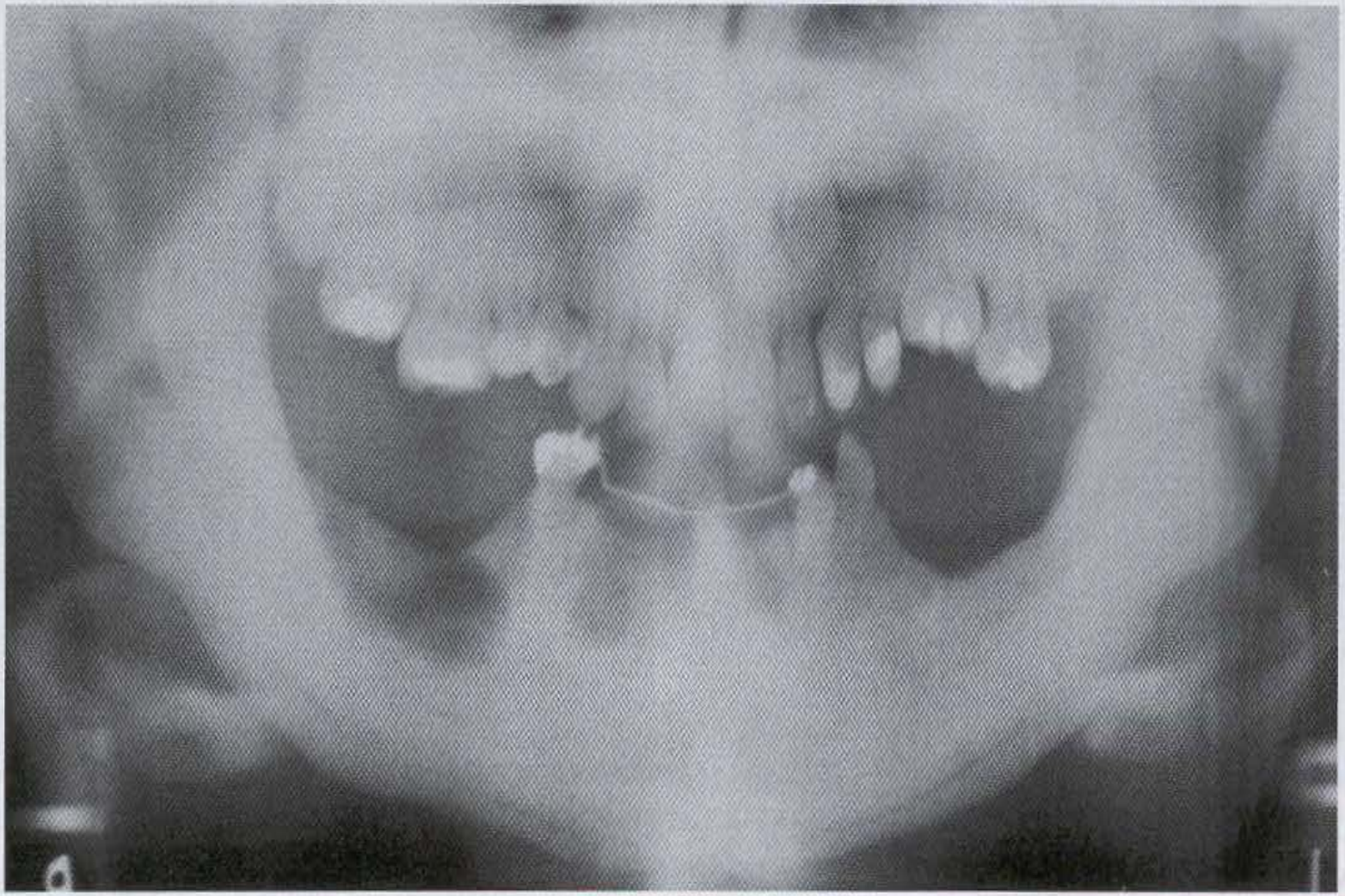

Osteopetrosis. Extensive mandibular involvement is apparent in this radiograph of a 31-year-old woman. She had been diagnosed as having osteopetrosis as a child. There is a history of multiple fractures and osteomyelitis of the jaws. (Courtesy of Dr. Dan Sarasin.)

Histopathologic Features

- Several patterns of abnormal endosteal bone formation have been described. These include the following:
- Tortuous lamellar trabeculae replacing the cancellous portion of the bone
- Globular amorphous bone deposition in the marrow spaces
- Osteophytic bone formation
- Numerous osteoclasts may be seen, but there is no evidence that they function because Howship 's lacunae are not visible.

Osteopetrosis.

sclerotic bone that is replacing the normal cancellous bone. The in set shows a nodular pattern of the dense bone obliterating the marrow spaces.

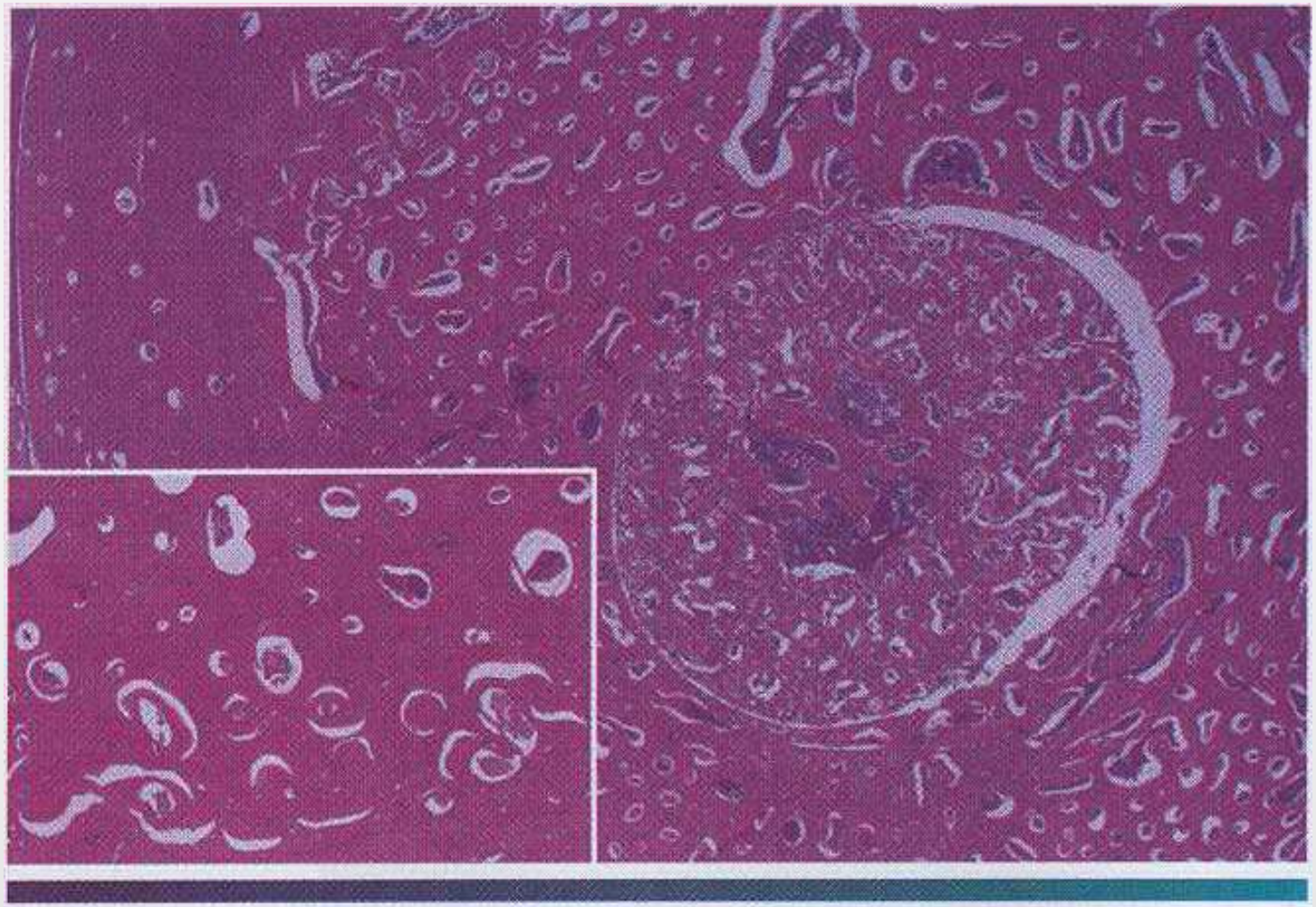

CLEIDOCRANIAL DYSPLASIA

Cleidocranial dysplasia.

The patient can almost approximate her shoulders in front of her chest.

Cleidocranial dysplasia. Panoramic radiograph showing multiple unerupted teeth

Histopathologic Features

- The reason for failure of permanent tooth eruption in patients with cleidocranial dysplasia is not understood well. Microscopic study of unerupted permanent teeth shows that these teeth lack secondary cementum.

FOCAL OSTEOPOROTIC MARROW DEFECT

- Defect is an area of hematopoietic marrow that is suf ficient in size to produce an area of radiolucency that may be confused with an intraosseous neoplasm.

Various theories include the following:

- Aberrant bone regeneration after tooth extraction.
- Persistence of fetal marrow.
- Marrow hyperplasia in response to increased demand for erythrocytes

Focal osteoporotic marrow defect.
a radiolucent area containing fine trabeculations.

ill-defined radiolucent areas located bilaterally in the molar edentulous regions (white arrows)

Histopathologic Features

- Microscopically, the defects contain cellular hematopoietic marrow, Lymphoid aggregates may be present.
- Bone trabeculae included in the biopsy specimen show no evidence of abnormal osteoblastic or osteoclastic activity

Focal osteoporotic marrow defect.
Photomicrograph showing normal hematopoietic bone marrow.

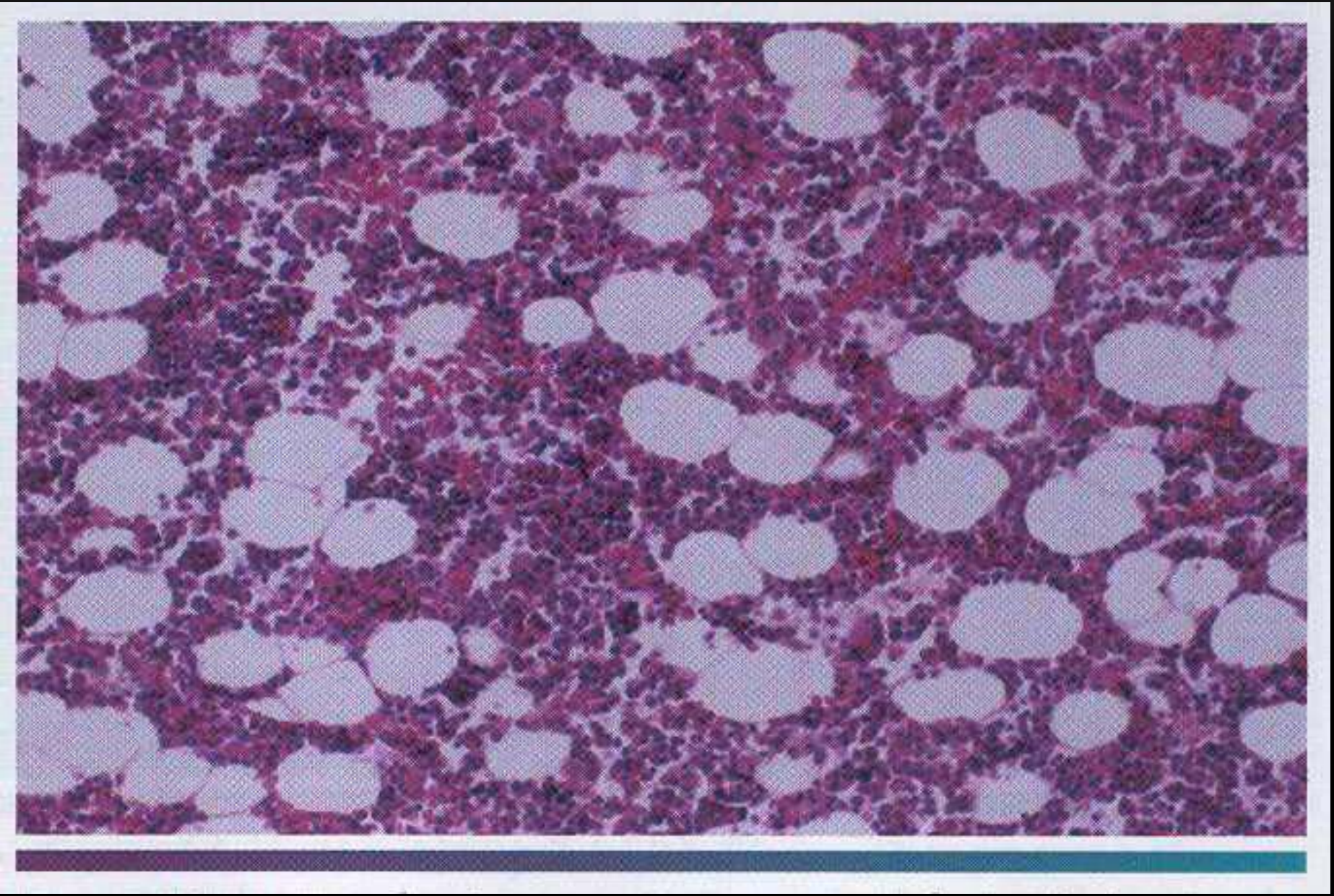

NORMAL HEMATOPOIETIC CELLS, FAT CELLS AND BONE TRABECULAE

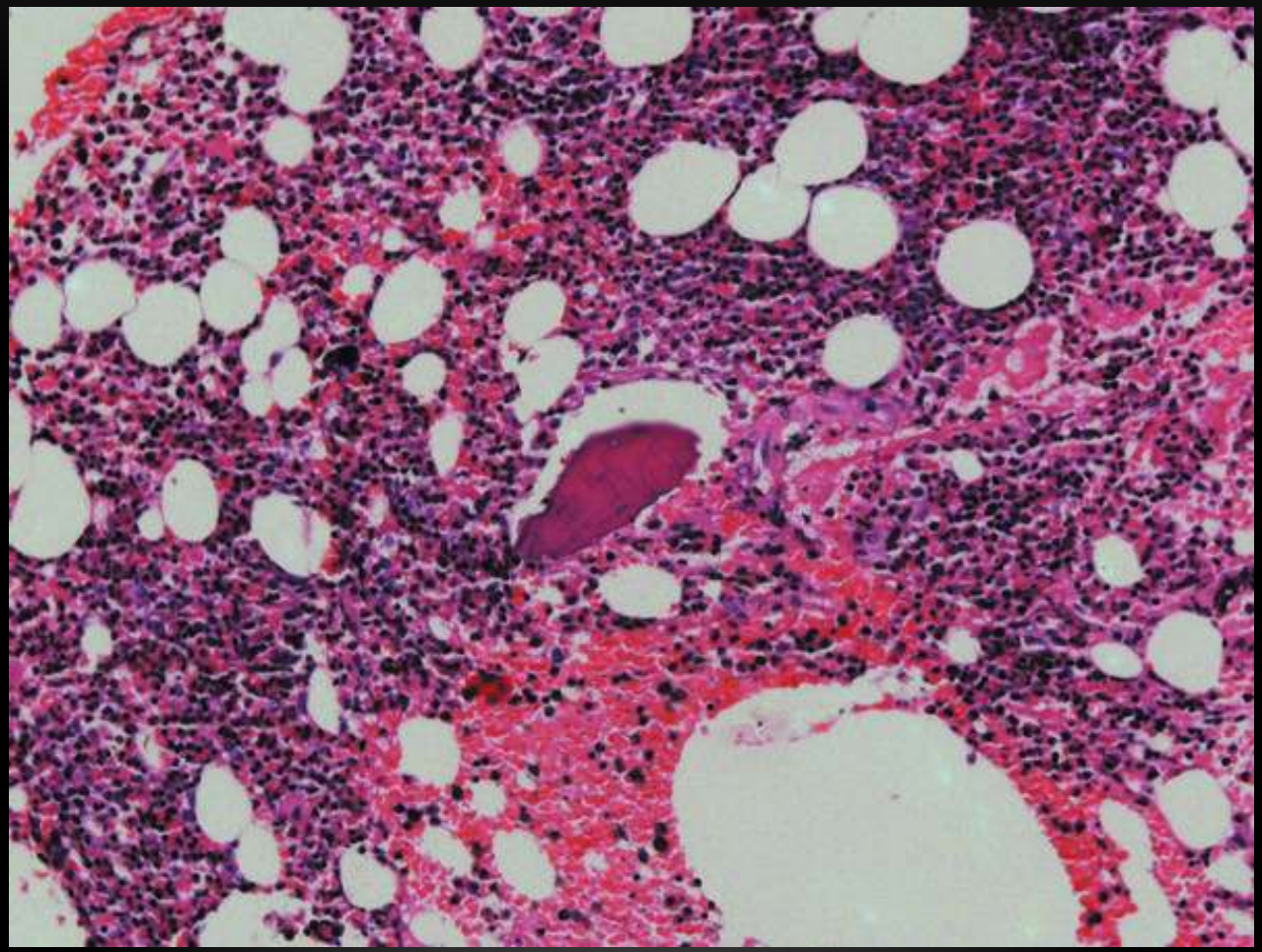

Paget's disease of bone(Osteitis Deformans)

- A DISEASE CHARACTERIZED BY **ABNORMAL RESORPTION AND DEPOSITION** OF BONE, RESULTING IN DISTORTION AND WEAKENING OF THE AFFECTED BONES.
- ASYMPTOMATIC DISEASE MAY BE DISCOVERED INCIDENTALLY WHEN RADIOGRAPHIC EXAMINATION OR SERUM ALKALINE PHOSPHATASE.

Paget disease. Maxillary enlargement with associated separation of teeth. (Courtesy Dr. Gordon Rick.)

Normal
Paget's disease

RADIOGRAPHICALLY

- **In early disease stages,**
- decreased radiodensity and a coarse trabecular pattern. Particularly in the skull,large circumscribed radiolucencies may be present (osteoporosis circumscripta).
- **In later disease stages,**
- patchy areas of bone sclerosis form and tend to become conf luent. The patchy sclerotic areas characteristically exhibit a **"cotton wool"** appearance. In addition, the teeth may demonstrate generalized hypercementosis.

PAGET DISEASE.

MARKED ENLARGEMENT OF THE CRANIUM WITH NEW BONE FORMATION ABOVE THE OUTER TABLE OF THE SKULL AND A PATCHY, DENSE, “COTTON WOOL” APPEARANCE.

A

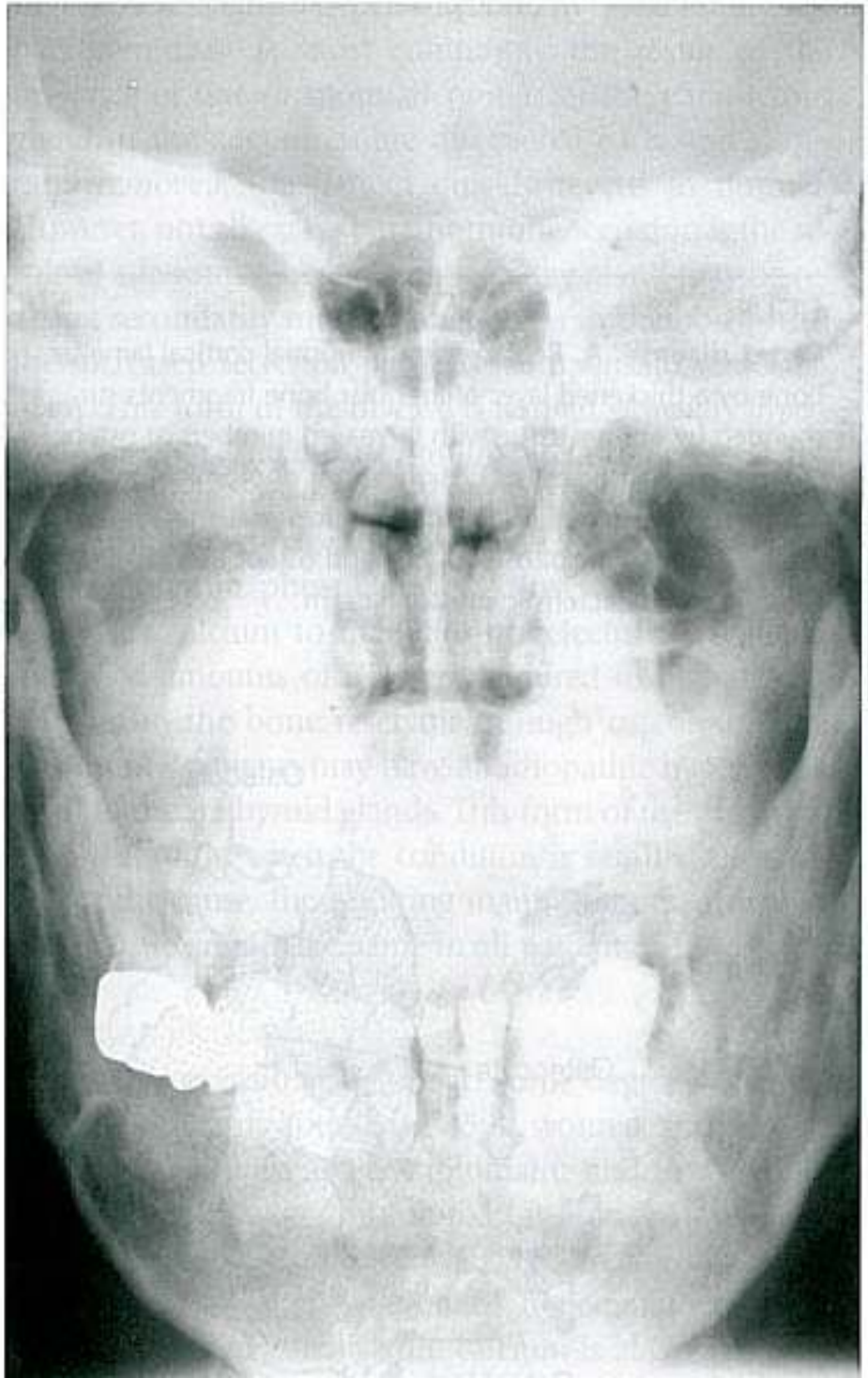

B

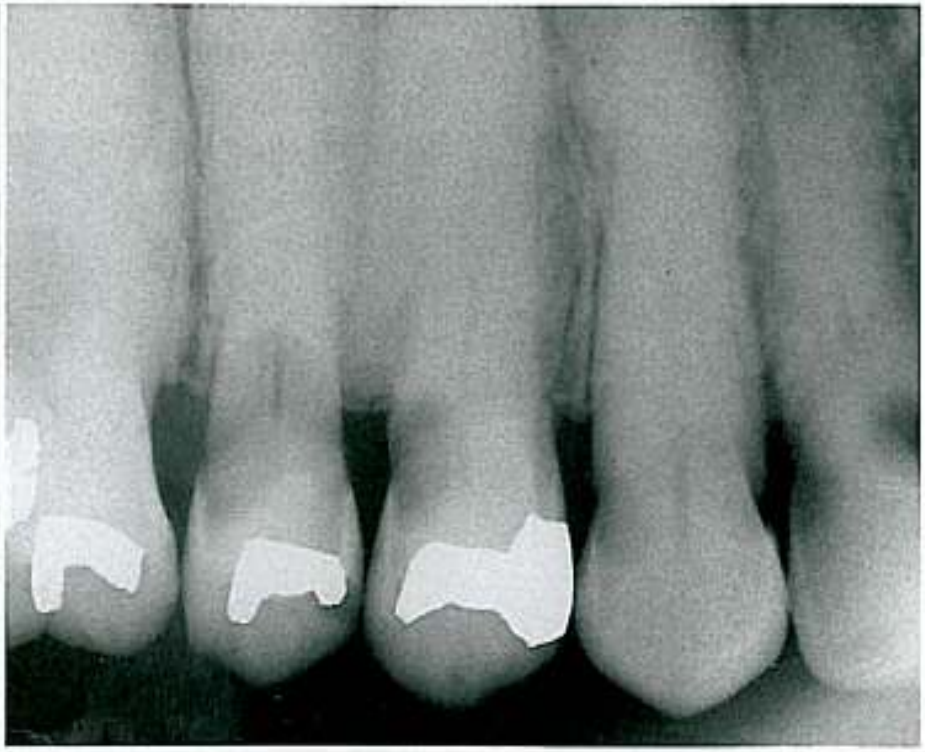

FIGURE 4-16

Paget disease. A, Mandible, maxilla, and part of cranium exhibiting a mottled mixture of radiopaque and radiolucent bone formation ("cotton ball" appearance). **B,** Periapical radiograph of teeth exhibiting hypercementosis and loss of lamina dura.

Paget's disease
"cotton wool" appearance of the bone.

HISTOPATHOLOGIC FEATURES

- Microscopic examination shows an apparent uncontrolled alternating resorption and formation of bone.
- In the active resorptive stages. numerous osteoclasts surround bone trabeculae and show evidence of resorptive activity. Simultaneously, osteoblastic activity is seen with formation of osteoid rims around bone trabeculae.

- A highly vascular f brous connective tissue replaces the marrow. A characteristic microscopic feature is the presence of **basophilic reversal lines in the bone.**

- These lines indicate the junction between alternating resorptive and formative phases of the bone and result in a "jigsaw puzzle. " or "mosaic." appearance of the b

- In the less active phases, large masses of dense bone showing prominent reversal lines are present.

A

B

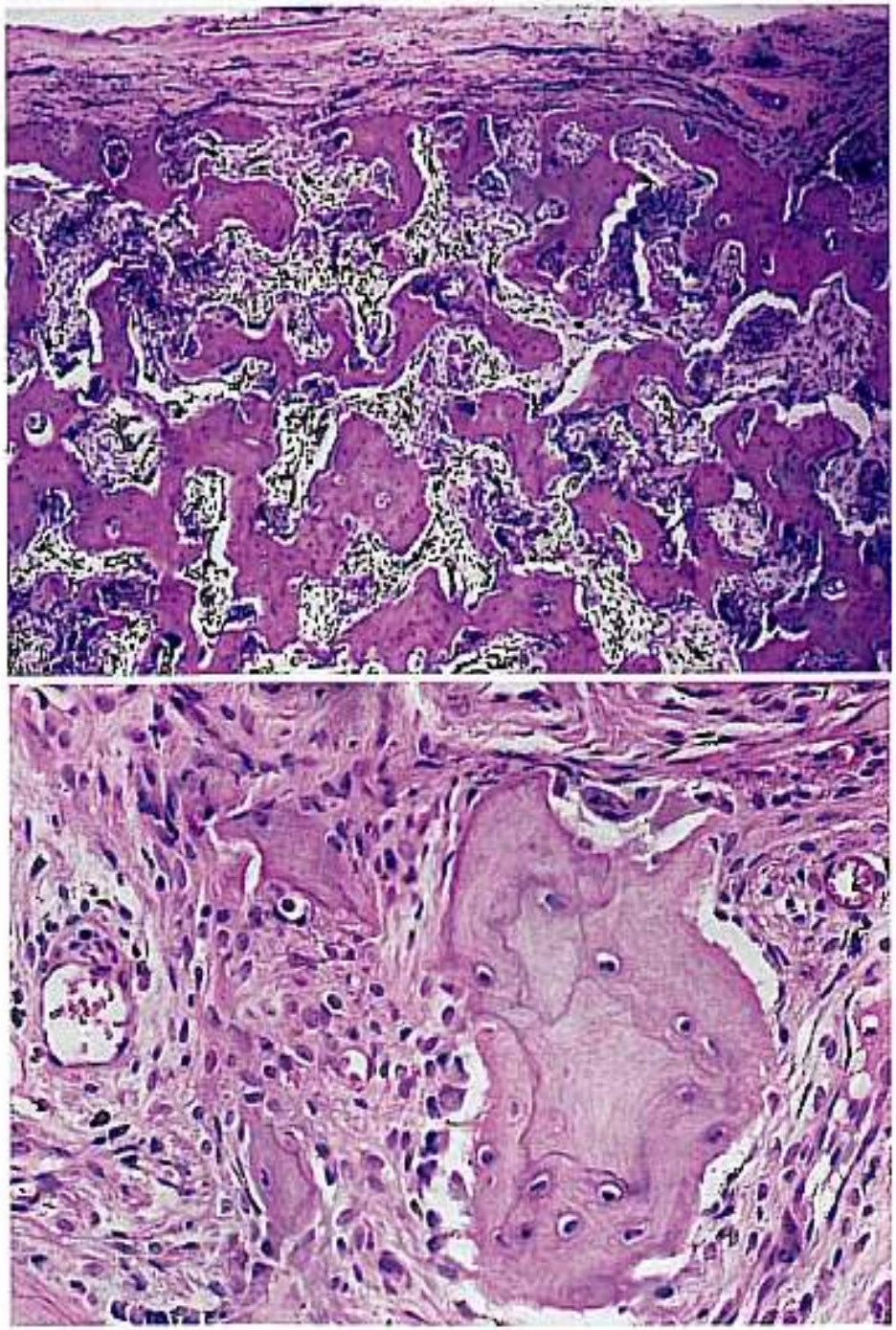

Paget disease. A, Replacement of normal cortical lamellar bone by a thickened layer of irregular bone fragments surrounded by fibrous tissue with increased numbers of osteoblastic and osteoclastic cells. **B,** High-power photomicrograph of fragment of pagetoid bone exhibiting reversal lines caused by multiple alterations of osteoblastic and osteoclastic activity, resulting in a characteristic mosaic pattern.

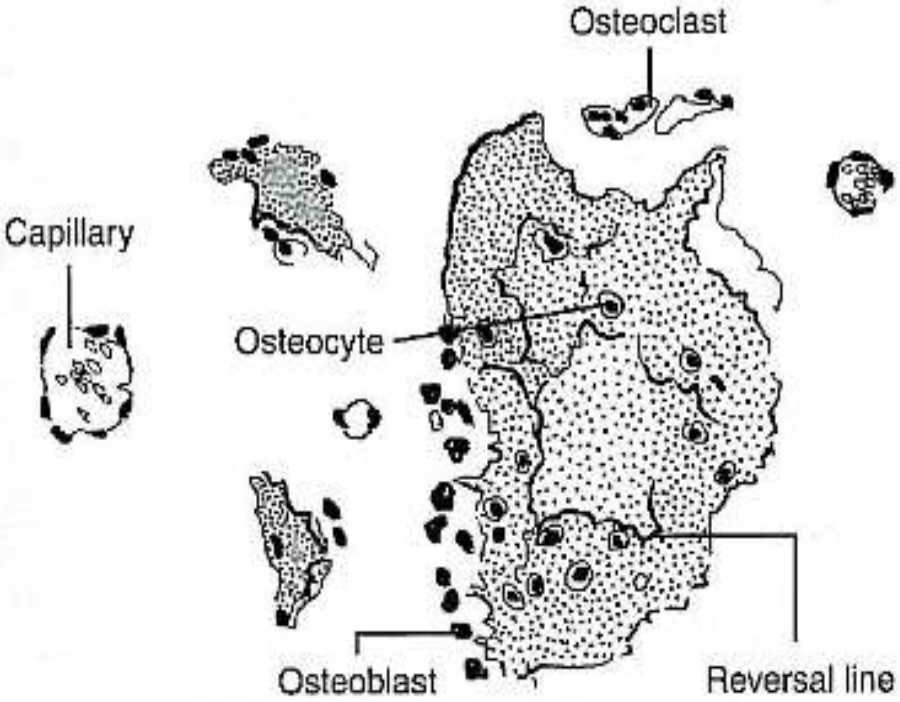

PAGET DISEASE.

PROMINENT OSTEOBLASTIC AND OSTEOCLASTIC ACTIVITY SURROUND THE BONE TRABECULAE. NOTE THE RESTING AND REVERSAL

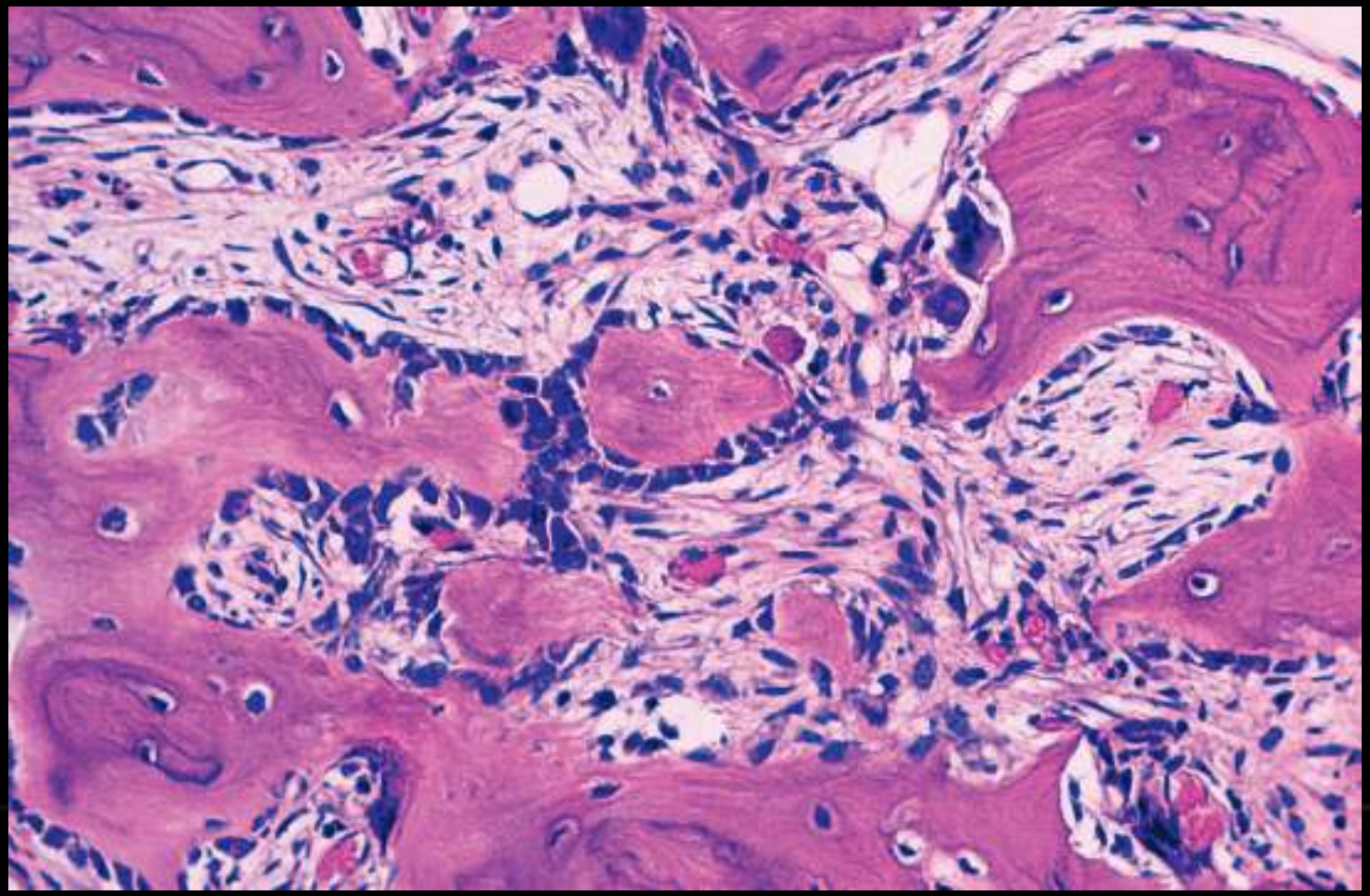

PAGET'S DISEASE OF BONE

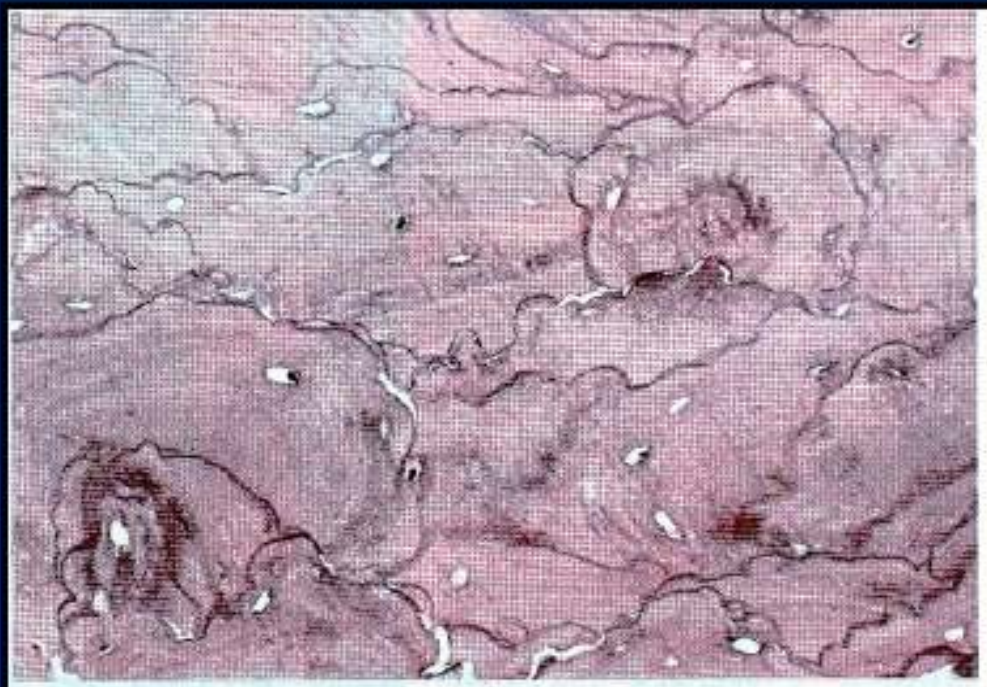

FIGURE 26–14 Mosaic pattern of lamellar bone pathognomonic of Paget disease.

EARLY CHANGES SHOWING PROMINENT OSTEOCLASTIC ACTIVITY

DIAGNOSIS

- Patients with Paget's disease show
- 1-high elevations in serum alkaline phosphatase levels but usually have normal blood calcium and phosphorus levels.
- 2-Urinary hydroxyproline levels also may be elevated markedly.
- 3-Newer and more sensitive markers of bone resorption are N-telo peptides and pyridine line cross-link assays.

- The clinical and radiographic features, combined with supportive laboratory findings, are typically sufficient for diagnosis.
- Histopathologic examination can be confirmatory but often is <u>unnecessary</u> for a strong presumptive diagnosis.

- Development of a malignant bone tumor, usually an osteosarcoma, is a recognized complication of Paget's disease.
- Benign and malignant giant cell tumors also may develop in bones affected by Paget's disease. Most of these occur in the craniofacial skeleton.